

Electrochemotherapy palliation of an oral squamous cell carcinoma in an African hedgehog (*Atelerix albiventris*)

Enrico Pierluigi Spugnini^{1*}, Andrea Lanza², Silvia Sebasti², Alfonso Baldi^{1,3}

¹ Biopulse Ltd., Naples, Italy; ² Gianicolense Veterinary Center, Rome, Italy; ³ Department of Environmental, Biological and Pharmaceutical Sciences and Technologies, University of Campania "L. Vanvitelli", Caserta, Italy.

Article Info	Abstract
<p>Article history:</p> <p>Received: 10 April 2018 Accepted: 24 July 2018 Available online: 15 December 2018</p> <p>Key words:</p> <p>African hedgehog Bleomycin Electrochemotherapy Squamous cell carcinoma</p>	<p>A five-year-old female African hedgehog (<i>Atelerix albiventris</i>) was referred for a one month growing oral mass. The hedgehog was quiet, alert and responsive, with a 1.00 × 1.50 cm ulcerated lesion on the mandible. The patient was staged with total body radiographs, hematological and biochemical analyses and the mass was biopsied under anesthesia. The excised tissue was reported to be a squamous cell carcinoma. At this time, due to the extension of the mass, a surgical excision was not a therapeutic option and the tumor was palliated with electrochemotherapy (ECT). Monthly sessions of ECT were performed using intra-lesional bleomycin injection followed by trains of biphasic electric pulses. The treatment was well tolerated and the patient remained in partial remission for five months until tumor progression. At that time the pet was euthanized. The ECT resulted in improved local control and should be considered as a possible adjuvant treatment in exotic pets with advanced tumors.</p>

© 2018 Urmia University. All rights reserved.

تسکین کارسینومای سلول سنگفرشی دهانی در یک جوجه تیغی آفریقایی توسط الکتروشیمی - درمانی

چکیده

یک جوجه تیغی آفریقایی ماده پنج ساله جهت یک توده دهانی در حال رشد به مدت یک ماه ارجاع داده شد. جوجه تیغی آرام، هوشیار، واجد عکس العمل، با زخمی به ابعاد ۱/۰۰×۱/۵۰ سانتیمتر بر روی فک پایین بود. بیمار مورد ارزیابی‌های پرتونگاری تمام بدن، خون‌شناسی و بیوشیمیایی قرار گرفت و توده در شرایط بیهوشی بافت برداری گردید. بافت برداشت شده کارسینومای سلول سنگفرشی گزارش شد. در این زمان، با توجه به گستردگی توده، برداشت جراحی گزینه درمانی نبود و تومور به واسطه الکتروشیمی درمانی تسکین داده شد. جلسات الکتروشیمی درمانی ماهیانه با استفاده از مجموعه ضربان‌های الکتریکی دو مرحله‌ای متعاقب تجویز داخل ضایعه‌ای بلنومایسین انجام پذیرفت. درمان به خوبی تحمل شد و بیمار برای مدت پنج ماه تا زمان پیشرفت تومور در بهبودی نسبی باقی ماند. در آن زمان حیوان مورد بهمرگی قرار گرفت. الکتروشیمی درمانی موجب بهبود کنترل موضعی گردید و باید به عنوان یک درمان مکمل انجام‌پذیر در حیوانات خانگی نامتعارف دارای تومورهای پیشرفته مدنظر قرار گیرد.

واژه های کلیدی: الکتروشیمی درمانی، بلنومایسین، جوجه تیغی آفریقایی، کارسینومای سلول سنگفرشی

*Correspondence:

Enrico Pierluigi Spugnini. DVM, PhD, Diplomate ACVIM (Oncology), Diplomate ECVIM-CA (Oncology)
Biopulse Ltd., Naples, Italy.

E-mail: enrico@onkodisruptor.com



This work is licensed under a Creative Commons Attribution-NonCommercial 4.0 International License which allows users to read, copy, distribute and make derivative works for non-commercial purposes from the material, as long as the author of the original work is cited properly.

Introduction

African hedgehogs (*Atelerix albiventris*) are increasingly becoming popular domestic pets in western countries. Neoplasia has been progressively reported in this species, with cancer being diagnosed in up to 50.00% of older hedgehogs.^{1,2} Most of these neoplasms are malignant and are associated with a poor prognosis.¹ The skin and adnexa are the most commonly affected locations; however, tumors have been reported in different body locations.^{1,3} From the histogenetic perspective, the large majority of cancers observed in African hedgehogs are of epithelial origin, with documented cases of differently localized carcinomas of skin and adnexa, as well as epithelial tumors of the digestive, endocrine, respiratory and reproductive systems.¹⁻⁴ Oral squamous cell carcinoma (SCC) is a common form of malignancy in hedgehogs and usually presents as a locally invasive tumor with a low tendency to metastasize.^{1,4,5}

Electrochemotherapy (ECT) is a loco-regional therapy that combines the administration of chemotherapy drugs with electric pulses displaying high voltage and square or biphasic shape.⁶ Electric pulses permeabilize the tumor cell membrane and this, in turn, enhances the delivery of lipophobic drugs such as bleomycin and cisplatin. The consequences are augmented local efficacy of the drugs with the possibility to use decreased doses of chemotherapy agents, thus limiting morbidities while preserving effectiveness.⁷ The ECT is actually considered among the different accepted therapeutic strategies that are used to treat tumors in pets. In this article, we present the first case of cancer in an African hedgehog treated with ECT.

Case Description

A five-year-old female spayed hedgehog was referred for an oral mass rapidly growing over one-month period. The animal was quiet, alert and responsive and a 1.00 × 1.50 cm ulcerated mass was protruded on rostral mandible (Fig. 1A). The patient was anesthetized using intramuscular 0.10 mg kg⁻¹ butorphanol tartrate (Dechra, Turin, Italy) combined with 0.10 mg kg⁻¹ medetomidine (Dechra) followed by 3.00% isoflurane (Baxter, Deerfield, USA) on oxygen administered using a small induction chamber and the lesion was biopsied. The animal was discharged on oral meloxicam (0.10 mg kg⁻¹, q24hr; Boehringer Ingelheim, Milan, Italy), enrofloxacin (7.50 mg kg⁻¹, q24hr; Bayer, Milan, Italy) and ranitidine (0.10 mg kg⁻¹; q12hr, Ceva, Agrate Brianza, Italy), all for seven days. The tissue was fixed in 10% buffered formalin and embedded in paraffin. Four μm thick sections were stained with hematoxylin and eosin.

Results

The histopathology report came back with a diagnosis of incompletely excised moderately differentiated SCC

characterized by squamous differentiation and invasive growth with basement membrane disruption (Fig. 1B). Due to the advanced stage of the neoplasm and the fact that these pets cannot correctly feed themselves in case of mandibulectomy, surgery was not a therapeutic option. At this point, the options to increase the chances of local control were included radiation therapy (modifying protocols already in use for ferrets) or electrochemo-therapy.^{7,8} The owner elected the patient to be treated with ECT. After providing total body radiographs to rule out metastatic spread, the tumor mass was injected with bleomycin (Bleomicina Solfato; Sanofi Aventis, Milan, Italy) at the concentration of 1.50 mg mL⁻¹ (total volume of 1 mL), (Fig. 1C). Five min after the injection, trains of 8 biphasic pulses at the voltage of 1200 V cm⁻¹, 1 Hz frequency, lasting 50 + 50 μsec with 300 μsec interpulse (total treatment time per cm of 3.20 msec) were administered using a clinical electroporator (Onkodisruptor®, Biopulse Ltd., Naples, Italy) certified for veterinary use (Fig. 1D). The procedure was performed with the patient under anesthesia as described above. The patient did not show any side effects due to the therapy and was discharged. The patient experienced a 25.00% tumor reduction (Fig. 1D, inset) and monthly ECT was performed thereafter combined with total body radiographs.

The patient's disease remained stable for a total of five months, then progressed and, at that time, the owner elected euthanasia.

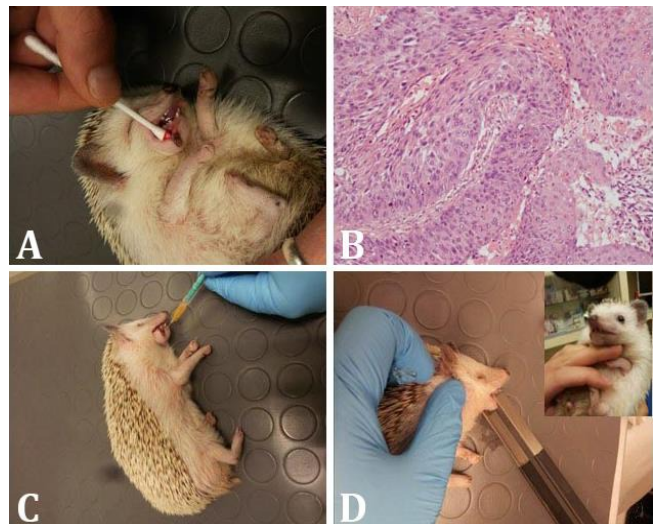


Fig. 1. **A)** The five-year-old female spayed hedgehog at presentation; **B)** The histopathological appearance of the lesion: The tumor tissue is composed of trabeculae and cords of neoplastic cells with invasive growth, disruption of the basement membrane and extension into the underlying tissue (Hematoxylin and Eosin, original magnification 10×); **C)** The tumor mass is being injected with bleomycin; **D)** Permeabilizing electric pulses are delivered to the patient through caliper electrodes connected to Onkodisruptor® electroporator; **D, inset)** An approximate 25.00% tumor reduction is visible after ECT treatment.

Discussion

The SCCs of the oral cavity of African pygmy hedgehogs have been well-documented.¹ Oral SCC is the most frequently diagnosed neoplasia of the digestive tract in this species and the third most frequent cancer, after mammary gland adenocarcinoma and lymphoma.³ Oral SCC is usually described as a locally invasive tumor, although one review has mentioned a case associated with metastasis to lymph node and lungs.² The other reported location of SCC in hedgehogs is the skin.³

The ECT successfully combines the administration of lipophobic antitumor agents such as bleomycin with permeabilizing high voltage electric pulses to treat several tumor histotypes in different body locations.⁷ Exclusive features of ECT such as high selectivity and efficacy for hitting neoplastic targets while at the same time sparing the local immune response and the connective organ scaffold are making this technique a valuable clinical asset.⁸ Bleomycin was chosen since it is the drug of election for ECT that greatly increases its uptake, the dose was calculated following the literature guidelines.⁹

Oral SCC has been described in hedgehogs, but the advanced stage of disease and its rapid progression prevented therapeutic approaches resulting in death of the pets.³ These data are consistent with our case that developed a single non-healing ulcerated lesion that remained localized in mandible without systemic spread.

The histopathology report described a moderately differentiated SCC as per current literature. The location of the lesion prevented surgical excision, orienting us towards palliative approaches. Due to the absence of reports on systemic chemotherapy in Erinaceidae, the authors elected to treat the hedgehog with locally injected bleomycin. To maximize its efficacy, trains of permeabilizing electric pulses were administered as described.¹⁰ The ECT allowed for extended tumor control without side effects and with a preservation of stomatognathic function. The ECT has been proved to be an effective therapeutic strategy in veterinary oncology on different tumor histotypes and animal species.¹¹ In our patient, we had an enhanced efficacy and lack of chemotherapy toxicity. The shorter duration of the train of pulses also accounted for the limited morbidity observed in our patient. In conclusion, ECT is a reliable strategy that could be considered among the oncological therapies in exotic pets as an adjunct post-surgical treatment or for palliative purposes. To the best of our knowledge, this is the first reported case of ECT not only in African hedgehogs but also in exotic mammals. Further investigations are warranted to validate these preliminary observations in exotic pets to consolidate the use of this alternative therapy in such species. It is well known that the chemotherapy protocols in exotic pets (including also birds and reptiles) are still in a very early stage of development and ECT, due to its local applications

is becoming an appealing and recognized therapeutic alternative, as evidenced by recent publications.¹²

Conflict of interest

Enrico Pierluigi Spugnini and Alfonso Baldi are founders and stockholders of Biopulse Ltd., producer of Onkodisruptor®.

References

1. Raymond JT, Garner MM. Spontaneous tumors in captive African hedgehogs (*Atelerix albiventris*): A retrospective study. *J Comp Pathol* 2001; 124(2-3): 128-133.
2. Raymond JT, White MR. Necropsy and histopathologic findings in 14 African hedgehogs (*Atelerix albiventris*): A retrospective study. *J Zoo Wildl Med* 1999; 30(2): 273-277.
3. Heatley J, Mauldin G, Cho D. A review of neoplasia in the captive African hedgehog (*Atelerix albiventris*). *Semin Avian Exotic Pet Med* 2005; 14(3): 182-192.
4. Couture ÉL, Langlois I, Santamaria-Bouvier A, et al. Cutaneous squamous cell carcinoma in an African pygmy hedgehog (*Atelerix albiventris*). *Can Vet J*. 2015; 56(12): 1275-1278.
5. Rivera RY, Janovits EB. Oronasal squamous carcinoma in an African hedgehog (*Erinaceidae albiventris*). *J Wildl Dis* 1992; 28(1): 148-150.
6. Spugnini EP, Baldi A. Electrochemotherapy in veterinary oncology: From rescue to first line therapy. *Methods Mol Biol* 2014; 1121: 247-256.
7. Spugnini EP, Azzarito T, Fais S, et al. Electrochemotherapy as first line cancer treatment: Experiences from veterinary medicine in developing novel protocols. *Curr Cancer Drug Targets* 2016; 16(1): 43-52.
8. Heatley J. Hedgehogs. In: Mitchell M, Tully T (Eds). *Manual of exotic pet practice*. 1st ed. St. Louis, USA: Saunders Elsevier 2009; 433-455.
9. Spugnini EP, Baldi A, Vincenzi B, et al. Intraoperative versus postoperative electrochemotherapy in high grade soft tissue sarcomas: A preliminary study in a spontaneous feline model. *Cancer Chemother Pharmacol* 2007; 59(3): 375-381.
10. Spugnini EP, Melillo A, Quagliuolo L, et al. Definition of novel electrochemotherapy parameters and validation of their *in vitro* and *in vivo* effectiveness. *J Cell Physiol* 2014; 229(9): 1177-1181.
11. Spugnini EP, Pizzuto M, Filipponi M, et al. Electroporation enhances bleomycin efficacy in cats with periocular carcinoma and advanced squamous cell carcinoma of the head. *J Vet Intern Med* 2015; 29(5): 1368-1375.
12. Zehnder A, Graham J, Antonissen G. Update on cancer treatment in exotics. *Vet Clin North Am Exot Anim Pract* 2018; 21(2): 465-509.