

# Comparison of pathogenicity in IBDV isolates in embryonic eggs

P.R. BARRIOS; M.P. MORAES; SANTOS, B.M.<sup>1\*</sup>; E.S. OLIVEIRA; L.J. PENA; D.A. PENA; V. MAFRA; C. A. NEVES; M.R. ALMEIDA AND S.Y. MARIN

IBIOAGRO – Laboratório de Virologia Molecular Animal. Universidade Federal de Viçosa, Av. PH. Rolfs, s/n, 36571-000, Viçosa-MG, Brasil.

[\\*bmsantos@ufv.br](mailto:bmsantos@ufv.br)

---

The present study has with objective to isolate virus of tissue of avian with clinical sinless of the infectious bursal disease, to determine the pathogenicit of isolates viralis different in embryo of hen specific pathogen free and to compare with vaccinal sample. Twenty-one bursa samples suspicious of infectious bursal disease submitted to Unit of Poultry Health at Federal University of Viçosa and three vaccinal samples were tested. The viral isolation was accomplished in VERO cells, the virus was isolated in 14.28% (3/21) of field samples and in all vaccinal samples. The samples were standardized by its ability to provoke pathogenic effect in cellular culture and were inoculated in 10 days embryonic eggs. Liver, kidney, bursa, spleen and gut samples of each embryo were collected during 8 days and the macroscopic alterations evaluated. Half of each collected sample was stored at 4°C and the other half was fixed with 10% formol. The fixed samples were processed by paraffin inclusion method, dyed with hematoxylin and eosin and the microscopic alterations evaluated. Total RNA extraction was performed on those samples stored at 4°C by TRIZOL method and tested by RT-PCR technique. In anatomopathological observations inoculated embryos presented reduced size when compared to control embryos and organs with characteristic lesions of vascular injury. In RT-PCR test was possible to detect the presence of viral nucleic acid in each and every tissues, and the distribution of field isolated was larger when compared to vaccinal isolates. The results revealed that there is not much difference between lesions caused by field isolates with lesions caused by some of vaccinal samples.

---

**Keywords:** Infectious bursal disease virus; reverse transcription-polymerase chain and avian Birnavirus

## Introduction

The infectious bursal disease virus is an important pathological agent of poultry and since 1962 it has been related to great economical losses. Until now, an efficient vaccination protocol has not been established and faults in poultry immunization are generally described. These faults motifs are being searched and various causes have been quoted, from the emergence of pathogenic strains by mutations in the gene responsible for coding VP2, to bad usage of vaccines attenuated for low passage and vaccinal reversion (Berg, 2000). The aim of this work was to examine and compare field isolates pathogenicity with vaccinal strains. The aim of this work was to examine and compare field isolates pathogenicity with vaccinal strains.

## Materials and methods

Twenty-one bursa samples suspicious of infectious bursal disease submitted to Unit of Poultry Health at Federal University of Viçosa and three vaccinal samples were tested. The viral isolation was accomplished in VERO cells, the virus was isolated in 14.28% (3/21) of field samples and in all vaccinal samples. The samples were standardized by its ability to provoke pathogenic effect in cellular culture and were inoculated in 10 days embryonic eggs. Liver, kidney, bursa, spleen and gut samples of each embryo were collected during 8 days and the macroscopic alterations evaluated. Half of each collected sample was stored at 4°C and the other half was fixed with 10% formol. The fixed samples were processed by paraffin inclusion method, dyed with hematoxilin and eosin and the microscopic alterations evaluated. Total RNA extraction was performed on those samples stored at 4°C by TRIzol method and tested by RT-PCR technique.

## Results and discussion

In anatomopathological observations inoculated embryos presented reduced size when compared to control embryos and organs with characteristics lesions of vascular injury. In histopathological analysis lymphoid organs presented an accentuated lymphoid depletion, hepatocytes presented cytoplasmatic vacuolization and kidneys basophiles structures inside tubules (Santos, 2005). In RT-PCR test was possible to detect the presence of viral nucleic acid in each and every tissues, and the distribution of field isolates was larger when compared to vaccinal isolates (Lima et al., 1996). The results revealed that there is larger when compared to vaccinal isolates. The results revealed that there is not much difference between lesions caused by field isolates with lesions caused by some of vaccinal samples (Simon and Ishizuka, 2000). However, there are distinct distribution patterns in tissues that could indicate a variation on attenuation in some vaccinal samples. These results suggest that vaccinal samples could cause characteristics disease lesions and that the use of a determinate strain more or less.

---

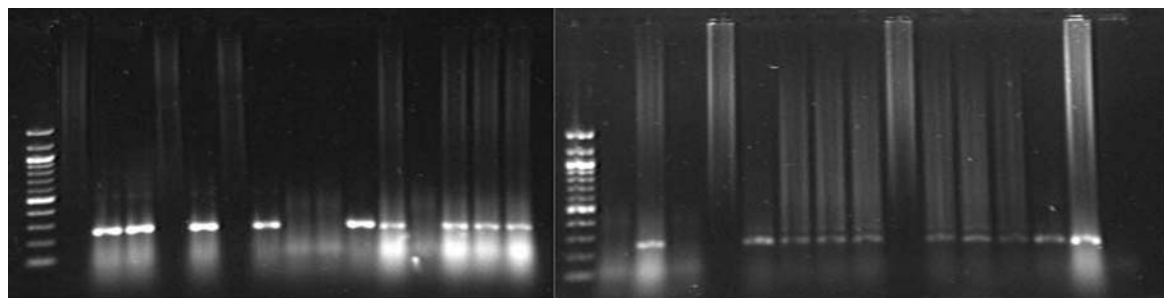
**Primer Forward: 804: 5'GTA ACA ATC ACA CTG TTC TCA G 3'**  
**Reverse: 1055: 5'GAT GGA TGT GAT TGG CTG GG 3'**

---

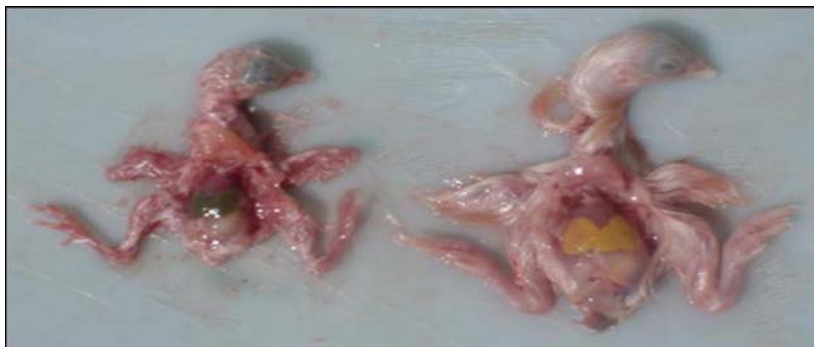

Figure 1 Anatomopathological observations, in the left side inoculated embryos presented reduced size when compared to control embryo in the right side.

M L K Bu S G L K Bu S G L K Bu S G M L K Bu S G L K Bu S G L K Bu S G



-----A----- -----B----- -----C----- -----1----- -----2----- -----3-----

Figure 2 Amplification of IBDV cDNA. M: 100 Kb DNA ladder marker (Life Technologies) L: liver, K: kidney, Bu: bursa, S: spleen, G: gut. A, B and C vaccinal samples. 1, 2 and 3 field isolates.

The resultados of the RT-PCR when associated with embryonic mortality, could to be aple to observe with the presence of viral RNA in the bursas is related with a larger pathogenicity of isolates. The drups A, C and 3 were positives to RT-PCR and showed 100% of mortality. In some sample some, not was possible isolate the viral RNA, However, they showed lesions. These results could to indicate that the virus were there and suffred mutation either then, that in the moment of the caught of the samples the viral title was decrease.

## Conclusion

These results suggest that vaccinal samples could cause characteristics disease lesions and that the use of a determinate strain more or less invasive should be evaluated with field professional.

## References

- BERG, T.P.** (2000) Acute infectious bursal disease in poultry: a review. *Avia Pathology* **29**: 175-194.
- LIMA, A.M.C.; SANTOS, B.M.; SILVA, P.L.** (1996) Distribuicao do virus da doenca infecciosa bolsa de Fabricio em embrioes de galinha. Conferencia APINCO 1996 de Ciencoa e Tecnologia Avicolas, Premio Lamas, *Anais*, p. 95.
- SANTOS, B.M.; FARIA, J.E.; RIBEIRO, V.V.** (2005) *Doenças virais de importancia nas aves*. n. **13**, pp 40-44. Vicosa: UFV.
- SIMON, V. A. and ISHIZUKA, M.M.** (2000) Doenca infecicosa de bolsa de Fabricio – DIB. *Doenca das aves*. Campinas: FACTA