

# Characterization of non-specific digestive disorders in turkey using intestinal morphometry

I. GABRIEL<sup>1\*</sup>, S. QUIMERC'H<sup>2</sup>, S. VIVIEN<sup>2</sup>, S. MALLET<sup>2</sup>, A. TRAVEL<sup>3</sup>, D. CHEVALIER<sup>4</sup> and I. BOUVAREL<sup>3</sup>

<sup>1</sup>INRA, UR83 Recherches Avicoles, F-37380 Nouzilly, France, <sup>2</sup>INRA, UR83 Recherches Avicoles, UMT ITAVI, INRA BIRD, F-37380 Nouzilly, France <sup>3</sup>ITAVI, UR83 Recherches Avicoles, UMT ITAVI, INRA BIRD, BP1, F-37380 Nouzilly, France, <sup>4</sup>Chambre Régionale des Pays de la Loire, ITAVI, F-49105 Angers, France

\* Corresponding author : [Irene.Gabriel@tours.inra.fr](mailto:Irene.Gabriel@tours.inra.fr)

---

We tried to characterize the non-specific digestive disorders (NSDD) that are increasing in turkey production using intestinal morphometry. Analyses were carried out on 304 turkeys (42 d) from 19 flocks. Turkeys were autopsied to distinguish healthy birds from those with specific or NSDD. Morphometry of the small intestine of healthy birds and birds suffering from NSDD was determined by a histological method (microdissection). Means were subjected to analysis of variance and compared by Student-Newman-Keuls test ( $p \leq 0.05$ ).

Turkeys with NSDD, non-specific enteritis (NSE) or maldigestion, had a lower body weight than healthy birds. Analysis of intestinal morphometry of turkey with NSE or maldigestion showed a lower intestinal villi development and an increased heterogeneity of the size of these structures. With maldigestion, intestinal crypt depth was increased. The heterogeneity of the crypt depth was increased with NSE or maldigestion. Thus, with NSDD, the smaller villi size led to lower digestive capacity of the intestine. With maldigestion, the increase in crypt depth, place of cell turn-over and mucus production, implied a significant nutritional cost for the animal which uses nutrients for digestive tract renewal instead of using it for its growth. Moreover, the heterogeneity of villi and crypts morphology showed a disorder in intestinal development. NSDD were characterized by important modifications of intestinal structure that might partly explain the lower body weights.

---

**Keywords:** non-specific digestive disorders; turkey; intestinal morphometry

## Introduction

These last years, new constraints were imposed in animal nutrition such as the ban of meat and bone meal and antibiotic growth promotants, the reduction in the number of coccidiostat or the ban of the only available antihistomonal in poultry. At the same time, an increase in digestive disorders was observed in poultry farms, and particularly in turkeys. These digestive disturbances can lead to diarrhoea and thus spoilage of the litter, a decreased feed intake and weight losses, and the prostration of birds. In turkey, various agents can be responsible for digestive pathologies, such as parasites (coccidiosis, histomonosis), mushrooms (candidosis), bacteria (collibacillosis, salmonellosis, necrotic enteritis) or viruses (haemorrhagic enteritis, reovirus, rotavirus, picornavirus ...). However in some cases, the agent responsible for an enteritis is unknown, and it is then a non-specific digestive disorder (NSDD).

In order to characterize the modifications of the intestinal morphology of birds with NSDD, the following study was performed.

## Materials and methods

Turkey poults of 42 d (males, BUT T9) were taken from 19 random French farms (16 birds / farm) to have a good representation of the state of animals. The turkeys were autopsied by veterinarians, which allowed to separate animals in several groups: healthy, ill without digestive disease, specific digestive disease (coccidiosis, candidosis, necrotic enteritis), maldigestion (presence of not digested feed in digestive contents), non-specific enteritis (inflammation of the intestinal wall or liquid/foam digestive content or not digested feed in digestive contents without recognized responsible agent), and not healthy at the digestive level without specific disease. The animals of the last two groups were thus grouped together under the term of non-specific enteritis (NSE). The healthy animals and those with NSDD (NSE or maldigestion) were then selected to analyze the morphometry of their small intestine.

To determine the morphometry of the intestine wall, the sampling was performed at the jejunal level (between duodenal loop and Meckel diverticle). A portion (0.5 cm in length) was taken at the median part, rinsed with saline (NaCl 9g/l), and treated as described by (Goodlad et al., 1991) to be analysed with a microdissection technique. For every sample, 10 villi and 20 crypts of Lieberkühn were analysed. For every villus and crypt, the height or the depth and the width were measured (Figures 1 and 2), and the surface was calculated. Moreover, for every sample, the coefficient of variation of each of the parameters was calculated; it represents the heterogeneity of the intestinal structure for a sample.

Data were analyzed using the Statview software (version 5). The averages were subjected to analysis of variance and compared by Student-Newman-Keuls test ( $p \leq 0.05$ ).

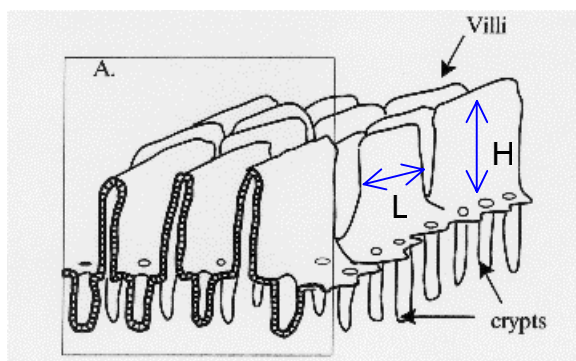


Figure 1. Diagram of villi and crypt of Lieberkühn of the small intestine (H: height; L: width)

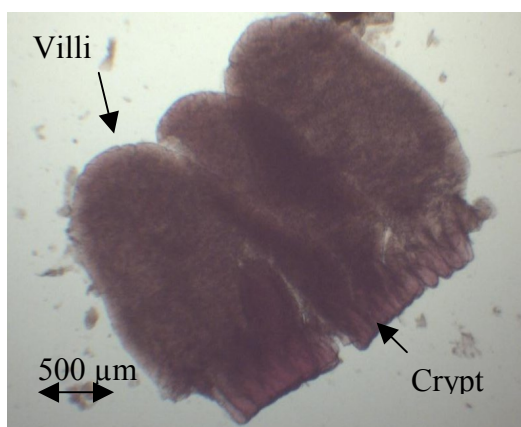


Figure 2. Villi with their crypts after dissection (Jejunum of turkey)

## Results and discussions

The histological technique used during this study is fast, inexpensive, and does not cause retraction artefact related with dehydration, contrary to the classical method embedding the sample in paraffin wax. Moreover, this technique allows to measure the width of the villi (Figure 1) and not their thickness as it is the case with the classical method. The surface calculated from the measure of the height and the width thus corresponds to the actual surface of the villus exposed to the intestinal lumen.

Among 304 sampled birds, 79% had digestive disorders of which 42% with specific disorders (coccidiosis, candidose, necrotic enteritis) and 58% with NSDD, distributed in NSE (40%) and maldigestion (18%).

Birds with NSDD (NSE or maldigestion) had lower weights than those of healthy animals, that is 14% and 24% respectively (Table). Turkeys with maldigestion had lower weight than those with NSE.

**Table. Histological measurements of the intestine wall (jejunum) of turkey (42 d)**

Parameter			Turkey group		
			Healthy	NSE <sup>1</sup>	Maldigestion
Number of birds			60	95	41
Number of flocks			6	11	5
Bird weight (g)			2204 ± 48 a	1888 ± 48 b	1680 ± 66 c
Measure	Villus	Hight (µm)	1516 ± 37 a	1296 ± 36 b	1234 ± 57 b
		Width (µm)	578 ± 18	535 ± 15	513 ± 28
		Surface (µm <sup>2</sup> )	895 888 ± 45 771 a	715 342 ± 34 938 b	680 904 ± 74 688 b
	Crypt	Depth (µm)	267 ± 9 b	272 ± 7 b	304 ± 9 a
		Width (µm)	65 ± 0.6	64 ± 0.8	65 ± 0.8
		Surface (µm <sup>2</sup> )	17 490 ± 670	17 688 ± 679	19 803 ± 731
Variation of measure (SE/mean x 100)	Villus	Hight (%)	6.3 ± 0.4 b	9.3 ± 0.4 a	8.0 ± 0.5 a
		Width (µm)	16.2 ± 0.6	18.2 ± 0.6	17.8 ± 0.8
		Surface (%)	19.5 ± 1.2	23.4 ± 1.0	20.4 ± 1.1
	Crypt	Depth (%)	6.2 ± 0.3 b	8.3 ± 0.3 a	7.4 ± 0.4 a
		Width (µm)	12.5 ± 0.5	14.0 ± 0.3	13.7 ± 0.6
		Surface (%)	14.9 ± 0.8 b	17.9 ± 0.6 a	16.3 ± 0.7 ab

(a-c) Mean (± standard error) with different letters for a given parameter differ significantly ( $p \leq 0.05$ )

<sup>1</sup> NSE : non-specific enteritis ; Includes birds diagnosed during the autopsy as being affected by not specific enteritis and those not healthy but without specific enteritis

Birds with NSE or maldigestion showed a smaller surface of the intestinal villi compared to the healthy animals, due to a decrease in the height of the villi, but without modification of their width (Table). Thus the surface of the villi of animals with NSE or maldigestion is 20 and 24 % smaller compared to the surface of the villi of the healthy animals. Moreover, an increase of the heterogeneity of the height of these structures in case of NSE and maldigestion was observed. Whereas no change in crypt size was observed in the presence of NSE, these were deeper in the case of maldigestion, which is 14 % more than the healthy animals. The heterogeneity of the crypt depth was increased with NSE as well as with maldigestion. Thus with NSDD, the size of the functional structures of hydrolysis and absorption of the intestine (villi) is decreased. These modifications of structure can reduce the capacities of digestion of the intestine. Thus positive correlations were observed between the height of the villi and the weight gain of piglets (Pluske et al., 1996). In the case of maldigestion, an increase of the crypt depth was observed. This is a common answer to any pathological process of the small intestine as enterocytes of the villi are affected (Kent and Moon, 1973). This increased crypt depth can be due to an increase of the cellular renewal as showed by the relation between the crypt depth and the activity of cellular proliferation (Brunsgaard and Eggum, 1995). This can also be due to an increase of secretions such as mucus produced by goblet cells particularly concentrated in crypts (Langhout et al., 1999). This stronger mucus production could reduce the diffusion of nutrients and thus decrease the digestion. In both the cases, the increase of the cellular renewal or the mucus production, this represents an additional metabolic cost for the animal which uses nutrients for the functioning of the

digestive tract instead of its growth. The lack of significant effect on the crypt depth in the case of NSE could be due to the fact that the NSE would be an intermediate step of NSDD, and the maldigestion a more advanced step. Moreover, the increase of the heterogeneity of the morphology of the villi and the crypts in the presence of NSDD shows a disturbance of the intestinal development.

These NSDD are thus connected to profound modifications of the intestinal structure, which could partially explain the lowest animal weights.

In conclusion, this study performed with a big number of animals raised in various conditions, showed that the intestinal structure of animals with NSDD is strongly modified compared to healthy animals. However, these results would need to be confirmed in animals raised in similar conditions with a more important follow-up, as it was not possible to determine in the present study if a possible 'farm effect' contributed to the observed differences between the three groups of animals. In this study, the intermediate segment of the small intestine was studied, but the proximal or distal part could also give information. The method used for histological analysis, a microdissection technique, has the advantage of being simple, fast and inexpensive, compared to the classical method embedding the sample in paraffin wax. Furthermore, it allows measuring the surface of the villi actually in touch with the intestinal lumen. This technique, still little used, can also be employed to reveal modifications due to the feed or to the use of alternatives to antibiotic growth promotants (Gabriel et al., 2005; Mallet et al., 2005).

### Acknowledgements

These works were performed with the financial support of the Cidef, the regional council of the 'pays de la Loire', the Ofival and the Adar.

### References

- BRUNSGAARD, G. and EGGUM, B.O.** (1995) Small intestinal tissue structure and proliferation as influenced by adaptation period and indigestible polysaccharides. *Comparative Biochemistry and Physiology. A, Physiology* **112A**: 365-377.
- GABRIEL, I., MALLET, S., LECONTE, M., LE HAGARAT, A. and LALLES, J.P.** (2005) Effet d'une alimentation à base de graines entières sur la flore digestive et la structure intestinale du poulet de chair, 2ème Congrès de la Société Française de Nutrition, Marseille, France, p. 132.
- KENT, T.H. and MOON, H.W.** (1973) The comparative pathogenesis of some enteric diseases. *Veterinary Pathology* **10**: 414-469.
- LANGHOUT, D.J., SCHUTTE, J.B., VAN LEEUWEN, P., WIEBENGA, J. and TAMMINGA, S.** (1999) Effect of dietary high- and low-methylated citrus pectin on the activity of the ileal microflora and morphology of the small intestinal wall of broiler chicks. *British Poultry Science* **40**: 340-347.
- MALLET, S., GABRIEL, I., PAVIOT, C., BERTIN, G. and LESSIRE, M.** (2005) Effet d'une supplémentation de l'aliment en MOS sur les performances, la flore intestinale, les organes immunitaires et la structure intestinale du poulet de chair, 2ème Congrès de la Société Française de Nutrition, Marseille, France, p. 132.
- PLUSKE, J.R., WILLIAMS, I.H. and AHERNE, F.X.** (1996) Maintenance of villous height and crypt depth in piglets by providing continuous nutrition after weaning. *Animal Science* **62**: 131-144.